

Clinical Outcome of Suture versus Fibrin Glue for Pterygium Excision

Mamata Choudhury¹, Jayapal Reddy²

Abstract

Aim of the study: To compare the clinical outcome of 8-0 vicryl suture versus fibrin glue in cases of pterygium excision with conjunctival autograft. *Materials and Methods:* A comparative prospective study was performed in forty eyes in forty patients in primary pterygium. The patient age ranged from thirty to sixty five years. They were randomly divided into two groups. Group A (20 eyes) who underwent pterygium excision with conjunctival autograft using 8-0 vicryl and Group B (20 eyes) with fibrin glue. Mean follow up period was for six months. Clinical assessment was done on first, seventh, thirtieth day and at the end of three months and six months. *Results:* The average surgical time for suture group was 30.56 minutes and in fibrin glue group it was 15.52 minutes. Postoperative symptoms like pain and foreign body sensation were significantly less in fibrin group compared to the suture group. Recurrence rates were not statistically different between the two groups. *Conclusion:* Use of fibrin glue in pterygium surgery gives postoperative comfort and also reduces surgical time.

Keywords: Pterygium Surgery; Conjunctival Autograft; Fibrin Glue.

Introduction

Pterygium is a wing shaped fold of conjunctiva encroaching on to the cornea. Prolonged exposure to hot, dry and dusty environments predisposes to the development of pterygium [1]. The main histopathological change in pterygium is elastotic degeneration of conjunctival collagen. Pterygium occurs mostly on nasal side, which can be attributed to light coming to the temporal cornea and being focused on the nasal cornea. Conjunctival autograft is the treatment of choice for pterygium surgery and this surgical procedure helps in preventing recurrence [2]. Fibrin glue when is used for pterygium surgery gives less postoperative pain and foreign body sensation [3]. There is paucity of published data comparing fibrin glue versus suture

in pterygium surgery from the Indian subcontinent. Hence we conducted this study.

Materials and Methods

Institutional ethics committee clearance was obtained before starting the study. This was a prospective study done in the department of Ophthalmology, Kamineni Institute of Medical Sciences and Sri Nethralaya, Hyderabad. Forty patients who presented at the outpatient department were included in the study after counselling. Informed consent was taken from all the patients. Patients were from age group of thirty to sixty five years.

Inclusion criteria

1. Primary nasal and temporal pterygium encroaching > one mm onto cornea
2. Uncomplicated pterygium

Pterygium was graded according to corneal involvement. (Grade 1: crossing limbus; Grade 2: midway between limbus and pupil; Grade 3: reaching up to pupillary margin and Grade 4: crossing pupillary margin) [4].

Author Affiliation: ¹Associate Professor ²Professor and Head, Department of Ophthalmology, Kamineni Academy of Medical Sciences and Research center, Hyderabad, Telangana 500068, India.

Corresponding Author: Mamata Choudhury, Associate Professor, Department of Ophthalmology, Kamineni Academy of Medical Sciences and Research center, Hyderabad, Telangana 500068, India.

E-mail: anilmamata@gmail.com

Received on 13.10.2017, Accepted on 30.10.2017

Exclusion criteria

1. Recurrent pterygium

Detailed clinical history was taken. Complete general, systemic and local examination and routine investigations were done for all the patients.

All the patients were explained about the advantages of fibrin glue. The patients were divided into two groups depending upon the spending capacity for the surgery. Group- A had twenty patients ie, twenty eyes for suture technique (suture group), and Group - B had twenty patients ie, twenty eyes for fibrin glue technique (fibrin glue group). In all cases visual acuity, slit lamp examination of anterior segment, dilated fundus examination and intraocular pressure recording was done. All surgeries were done by single experienced surgeon under operating microscope.

Peribulbar anaesthesia with 3 ml of 2% xylocaine and 0.5% bupivacaine 5ml of with 150 units/ml of hyaluronidase was given in all patients. Whole pterygium was removed starting from conjunctival side to corneal side. Corneal bed was scraped for any remnant of pterygium. Bare sclera length and breadth were measured with a caliper. Superior bulbar conjunctiva was infiltrated with ringers lactate. Only conjunctival epithelium was excised and tenon's capsule was left behind. Conjunctiva with epithelium side up was put on bare sclera and sutured with 8-0 vicryl in Group A. In Group -B patients, glue (Baxter Company) was prepared in two syringes. In one syringe thrombin and in other syringe fibrin was taken. Initially few drops of thrombin were put and then few drops of fibrin were put on scleral bed and immediately conjunctival graft was put. By using a Macpherson forcep the graft was sealed. Subconjunctival injection decadron 0.5 cc was given. The duration of the surgical procedure was noted in both the groups.

Post operatively, topical prednisolone eye drops six times daily for one week followed by 4x2x1 for three weeks, an antibiotic drop (moxifloxacin) for two weeks, 0.5% carboxymethylcellulose four times daily for one month were administered. Patients were examined on postoperative day one and were followed up at 1 week, 4weeks, 3months and 6 months. Patients were asked about any feeling of watering from the eyes, pain and/or foreign body sensation and were examined for any complications.

Observations and Results

A total of forty patients (forty eyes) underwent surgical excision for pterygium, and all patients

completed the 6-month follow-up (Table 1).

Table 1: Demographic data of patients in suture group and fibrin glue group

Case details	Group A	Group B
Number of cases	20	20
Age in years	44.4	46.8
Male	68	66
Female	32	34
Rural background	78	76
Urban background	22	24
Pterygium classification		
Grade 1	8	6
Grade 2	12	14
Maximum follow up period in months	8	8
Minimum follow up period in months	6	6

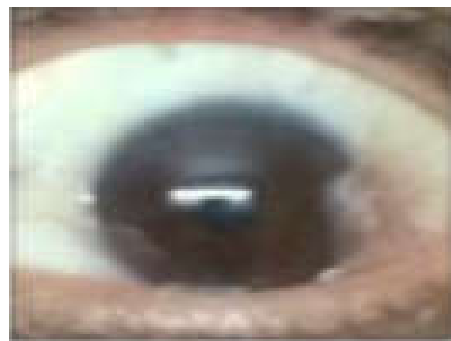

Fig. 1: Primary temporal pterygium

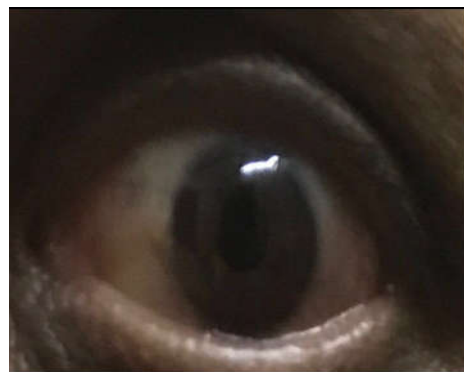

Fig. 2: Pterygium excision with conjunctival autograft with fibrin glue (Six month postoperative picture of same patient)

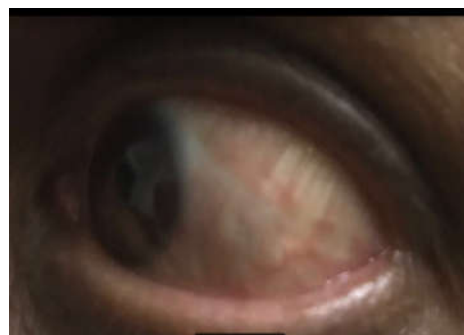


Fig. 3: Pterygium excision with conjunctival autograft with glue of same patient (Six month postoperative)

Table 2: Postoperative symptoms of patients in suture group and fibrin group

Symptoms	Day - 1		Day - 7	
	Group A (suture)	Group B (glue)	Group A (suture)	Group B (glue)
Watering	20	0	0	0
Chemosis	5	0	0	0
Foreign body sensation	20	0	10	0
Pain	20	0	0	0

Table 3: Complications associated with Pterygium excision in the suture group and fibrin glue group (3 Months and 6 Months)

Complications	3 Months		6 Months	
	Group A	Group B	Group A	Group B
Dehiscence	0	0	0	0
Ridge	3	0	3	0
Subgraft hemorrhage	4	2	0	0
Contracture	0	2	0	2
Recurrence	0	0	0	0
Total	12	5	3	2

Average operative time was 15.52 minutes (range, 15-20 minutes) in the fibrin glue group and 30.56 minutes (range, 30-40 minutes) in the vicryl suture group. The operating time was significantly less in the glue group versus suture group ($p = 0$). Patient complaints of pain, foreign body sensation, stinging and watering were scored for each group. All the four complaint scores on the first and seventh days were significantly lower in fibrin group (for chemosis and photophobia ($p = 0.001$) for pain and watering ($p < 0.001$). (Table 2)

Preoperative best corrected visual acuity (BCVA) in suture group was 6/6 in 24% of cases and 6/9 in 66% cases, 6/ 12 in 10% cases and for glue group 6/6 in 14% cases, 6/9 in 76% cases and 6/ 12 in 10% of cases . BCVA day 1 postoperative was (suture group 6/6 in 72% cases, 6/9 in 28% cases and for glue group 6/6 in 100% cases ($p = 0.83$). BCVA at 1 month after the operation was 6/6 in both groups. Corneal astigmatism was (suture group = 2.256 diopters) {glue group = 2.372 diopters) significantly reduced in the both group to (suture group = 0.382 diopters) (glue group = 0.362 diopters. There was no significant difference noted between the two groups with regard to postoperative correction of BCVA and corneal astigmatism. There were 4 episodes of small subconjunctival hemorrhage in the suture group (8%) and 2 in glue group. In 2 cases sutures needed to be removed because of suture irritation. Retraction of graft was seen in 2 cases in glue group. Ridges were seen in 3 cases in suture group. There were no other complications recorded.

Discussion

Pterygium surgery has possibility of recurrences. Thus, one can aim to reduce the number of recurrences by including the limbal stem cells in conjunctival autograft. There are several kinds of surgery for pterygium. Excision of the pterygium with conjunctival autografting is considered to be the procedure of choice in terms of efficacy and long-term stability [5]. The transplantation of conjunctivo-limbal autograft helps to cover the LSC deficiency [6]. Care should be taken to include the limbal part while harvesting the graft so that stem cells are included. Adjunctive therapies such as mitomycin C and excimer laser have also been used to decrease the recurrence rate of pterygium in spite of potentially sight-threatening side effects [7,8].

Treatment of pterygium with conjunctival autografts or amniotic membrane grafts after pterygium excision is reported to have the best and comparable success rates. These grafts have traditionally been affixed to the bare sclera bed using sutures. The presence of these sutures is believed to initiate a mild inflammatory response giving rise to symptoms of pain, grittiness and watering postoperatively and therefore, negating the purpose of the surgical intervention. The time consumption for the placement of sutures during surgery and the need to remove them later on makes it a lengthy and tedious process. Fibrin glue is a blood-derived product which consists of a fibrinogen component and a thrombin component. It imitates the final stages of the coagulation cascade when two components are mixed. Fibrin glue has also found its application in neurosurgery for the repair of dural leaks and for the treatment of atrophic rhinitis. In the field of ophthalmology, fibrin glue is being used in strabismus surgery, corneal surgery, amniotic membrane transplantation and conjunctival closure following pterygium [9,10]. There was no significant difference between the preoperative and postoperative BCVA between two groups Furthermore, there was no significant difference between the degrees of correction of corneal astigmatism between the two groups. This suggested that both the techniques are equally good in these aspects. There were four episodes of subconjunctival hemorrhage in the suture group. Uy et al. [11] in their series of 22 patients, used fibrin glue in 11 patients, and 10/0 nylon suture in other 11 patients and compared the two groups in terms of postoperative pain, foreign body sensation, and watering complaints. They concluded that all the complaints were significantly less in fibrin group. A significant difference was noted between the incidence of pain, photophobia, chemosis, and watering among the day 1 postoperative patients

of fibrin glue group versus the suture group. Our findings correlate with the other studies suggesting all symptoms are significantly less in fibrin glue group. All the postoperative patients recovered by day 14 postoperative in the suture group. The recurrence rate of pterygium, depending on the surgery type such as glue-assisted or suture-assisted autografting, has been a matter of controversy. Some reports [12] documented that the fibrin glue group showed lower recurrence rates than the suture group. Hall et al. [13] reported similar recurrence rates for the two groups. In our study, the small number of cohort patients and a short follow-up period could not determine the long-term recurrence rate of glue-assisted pterygium surgery. Nevertheless, we believe that less inflammation in the earlier postoperative stage may be related to a small chance of recurrence; this hypothesis corresponds with the result of a previous report on the correlation between inflammation and recurrence [6]. In our study, there were no cases of recurrence in both the groups were observed at 6 months follow-up. There was no recurrence in Group B. Yuksel et al. [14] conducted a prospective study on 58 cases and observed patient symptoms were significantly less in the fibrin glue group as compared to the suture group. There were 2 cases and 1 case of recurrence in the suture group and fibrin glue group, respectively. Farid and coworkers [15] conducted a retrospective study to evaluate the rate of recurrence after pterygium excision with autograft in 47 eyes. The recurrence rate in tissue adhesive group was 3.7% compared to 20% in suture group ($P = 0.035$). However, according to Marticorena et al. [16], Uy et al. [11] and Koranyi et al. [12] there was no recurrence in either group. Regarding other complications in glue-assisted pterygium surgeries, previous reports did not present much difference between glue-assisted and conventional pterygium surgeries.

Conclusion

The use of fibrin glue to attach the free conjunctival autograft in pterygium surgery produces shorter operating time, less postoperative discomfort and no recurrence rate compared to 8-0 vicryl sutures. Shorter surgery time logically translates into lower infection risk and also saves valuable operating theater time. The patient stands to benefit on account of an earlier return to normal life due to greater postoperative comfort.

References

1. Kaufman SC, Jacob DS, Lee WB, Deng SX, Rosenblatt MI, Shtein RM; Options and adjuvants in surgery for pterygium; A report by the American Academy of Ophthalmology. *Ophthalmology* 2013;120(1): 201-08.
2. Prabhasawat P, Barton K, Burkett G, Tseng SC. Comparison of conjunctival autografts, amniotic membrane grafts and primary closure for pterygium excision. *Ophthalmology* 1997;104:974-85.
3. Karalezli A, Kucukerdonmez C, Akova YA, Altan - Yaycoglu R, Borazan M. Fibrin glue versus sutures for conjunctival autografting in pterygium surgery; A prospective comparative study. *Br J Ophthalmol* 2008;92:1206-10.
4. Kodavoor SK, Dandapani R, Tiwari NN, Ramamurthy S. Double -head pterygium excision with modified technique of vertically split-conjunctival autograft. *Indian J Ophthalmology* 2017;65:700-4.
5. Ang LP, Chua JL, Tan Dt. Current Concepts and techniques in pterygium treatment. *Curr Opin Ophthalmol* 2007;18:308-13.
6. Coroneo MT, Di Girolamo N, Wakefield D. The pathogenesis of pterygia. *Curr Opin Ophthalmol* 1999;10:282-8.
7. Talu H, Tasindi E, Ciftci F, Yildiz TF. Excimer laser phototherapeutic keratectomy for recurrent pterygium. *J Cataract Refract Surgery* 1998;24:1326-32.
8. Lewallen S. A randomized trial of conjunctival autografting for pterygium in the tropics. *Ophthalmology* 1989;96:1612-4.
9. Lagoutte FM, Gauthier L, Comte PR. A fibrin sealant for perforated and preperforated corneal ulcers. *Br J Ophthalmol* 1989;73:757-61.
10. Hick S, Demers PE, Brunette I, La C, Mabon M, Duchesne B. Amniotic membrane Transplantation and fibrin glue in the management of corneal ulcers and perforations: A review of 33 Cases. *Cornea* 2005;24:369-77.
11. Uy HS, Reyes JM, Flores JD, Lim Bon Siong R. Comparison of fibrin glue and sutures for attaching conjunctival autografts after pterygium excision. *Ophthalmology*. 2005 Apr;112(4):667-71.
12. Koranyi G, Seregard S, Kopp ED. The cut and paste method for primary pterygium surgery long term follow up. *Acta Ophthalmol Scand* 2005;83:298-301.
13. Hall RC, Logan AJ, Wells AP. Comparison of fibrin glue with sutures for pterygium excision surgery with conjunctival autografts. *Clin Experiment Ophthalmol* 2009;37:584-9.
14. Yuksel B, Unsal SK, Onat S. Comparison of fibrin glue and suture technique in pterygium surgery performed with limbal autograft. *Int J Ophthalmology* 2010;3:316-20.
15. Farid M, Pirnazar Jr. Pterygium recurrence after excision with conjunctival autograft: A comparison of fibrin tissue adhesive to absorbable sutures. *Cornea* 2009;28:43-5.
16. Marticorena J, Rodriguez-Ares M T, Tourino R. Pterygium surgery: conjunctival autograft using a fibrin adhesive. *Cornea*. 2006;25(1)34-36.